

# Augmentation Mammoplasty With Saline-filled Textured Implants: Review of 9 Years' Experience and Results of Patient Survey

Jacob Haiavy, MD; Howard A. Tobin, MD

**Introduction:** In June of 2000 the FDA approved saline-filled breast implants as safe prosthetic devices based on results of clinical testing presented by the manufacturers. The corresponding author has been using saline-filled implants since 1992. It was decided to review his experience and assess the incidence of postoperative complications as reported by the patients and to identify factors related to their satisfaction.

**Materials and Methods:** A survey was mailed out to a cohort of 460 patients. The survey included questions pertaining to possible postoperative complications and the patient's overall satisfaction. Overall, 207 surveys were returned after 2 mailings. Statistical analysis was performed using the Statistical Package for the Social Sciences (SPSS) software.

**Results:** The patient's age at the time of surgery ranged from 18 to 62 years, with a mean of 33.8 years. Follow-up time ranged from 6 months to 102 months postoperatively, with a mean of 37.2 months. Forty-two out of 193 patients were smokers. Implant volumes ranged from 180 to 800 mL, with an average of 380 mL. Implant types used were Mcghan (55.5%), Mentor (40.5%), and Microcell (4%). All implants had surface texturing. Most of the implants (90.7%) were placed in a submuscular position. Sixty-five percent of the patients preferred a transaxillary approach, whereas 35% preferred the periareolar approach.

**Discussion:** Capsular contracture remains one of the main factors affecting patient satisfaction. Implant volume and position had no significant effect on the risk of developing capsular contracture. Furthermore, the volume of an implant did not have a significant impact on the risk of developing pain, loss of nipple sensation, or wrinkling. In this study, a significant number of patients reported wrinkling (44.4%) and alteration of nipple sensation (40.6%), which reflects the fact that this is a subjective patient-reported result. Overall satisfaction rate reported was 96.6%.

Augmentation mammoplasty is one of the most common cosmetic procedures performed in the United States today. It is estimated that approximately 3 million women have undergone breast augmentation. From the 1960s to 1992, most of the implant prostheses were filled with silicone gel. On April 16, 1992, the Food and Drug Administration (FDA) banned further use of these devices because of a few reports that linked these implants to a variety of illnesses such as connective tissue diseases or rheumatic illnesses.<sup>1</sup> Although subsequent studies found no supporting evidence linking gel-filled implants to autoimmune diseases,<sup>2</sup> saline-filled implants have become the prosthetic of choice.

In June 2000 the FDA approved saline-filled breast implants as safe prosthetic devices. This decision was based on the results of clinical testing carried out by the two-implant manufacturers (McGhan and Mentor).<sup>3,4</sup>

Although declared as generally safe, these devices are not devoid of problems. Unfortunately, there are few reports with a sufficient number of patients with long-term follow-up that assess the outcome and complications as reported by the patients. The corresponding author has been using saline-filled implants since 1992; he decided to review his experience from May 1992 to June 2000.

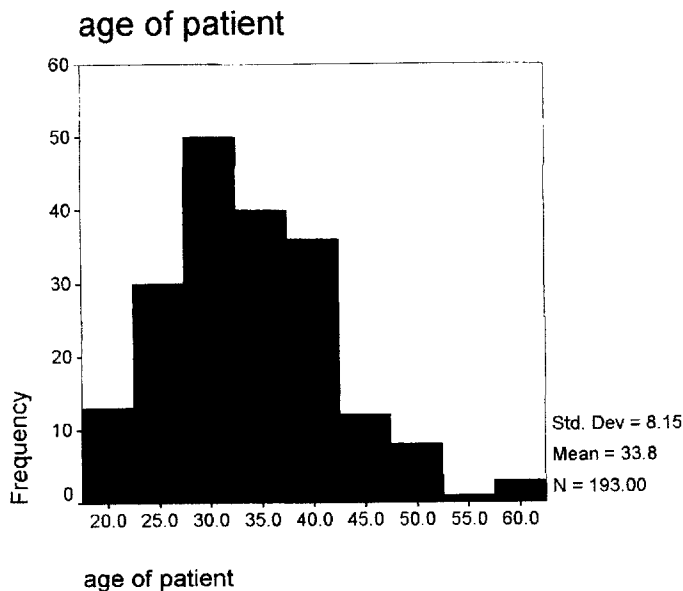
## Materials and Methods

A survey containing 12 questions was mailed to a cohort of 460 patients who had undergone cosmetic breast augmentation with textured saline implants at the Facial Plastic and Cosmetic Surgical Center in Abilene, Tex., between May 1992 and June 2000. Patients undergoing reconstructive procedures were not included in this study. The survey included questions pertaining to possible postoperative complications such as bleeding, infection, leakage, capsular contracture, pain, wrinkling, and loss of sensation. The study assessed patients' overall satisfaction and their feeling as to whether they would undergo breast augmentation again. The medical records of the responding patients were then examined for demographic data and surgical information such as the type, volume, and anatomical

Received for publication October 22, 2001.

From the Facial Plastic and Cosmetic Surgical Center in Abilene, Tex.

Corresponding author: Dr Howard A. Tobin, MD, 6300 Humana Plaza, Suite 475, Abilene, TX 79606 (e-mail: n41gt@abilene.com).



**Figure 1.** The age of the patients at the time of surgery.

placement of the implant. Women who did not respond to the survey received a second mailing of the questionnaire.

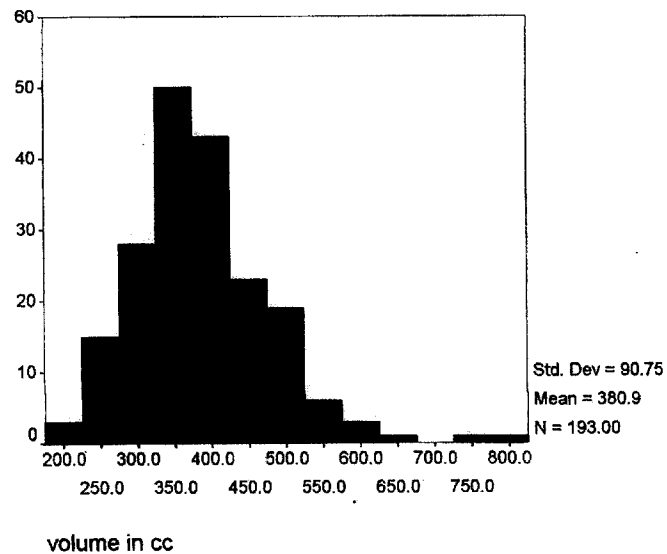
Overall, 207 surveys were returned by the patients after 2 mailings. One hundred nineteen of the surveys were returned by the post office as undeliverable.

Statistical analysis was performed using the Statistical Package for the Social Sciences (SPSS, SPSS Inc, Chicago, Ill) software. One-way analysis of variance (ANOVA) was used to look for influences of variables that were continuous, such as time since augmentation and volume of implant fill on the risk of developing complications. Chi-squared analysis was used to look for differences among discrete variables. This was used to determine which parameters had a significant effect on the risk of developing capsular contracture, pain, bleeding, wrinkling, and loss of sensation and which parameters had a significant effect on patient overall satisfaction. Alpha was 0.05 for all investigations.

### Results

One hundred ninety-three of the 207 surveys returned had demographic data available. The patient's age at the time of surgery ranged from 18 to 62 years, with a mean of 33.8 years (Figure 1). Follow-up time ranged from 6 months to 102 months postoperatively, with a mean of 37.2 months. Forty-two out of 193 patients were smokers. The authors prefer not to operate on smokers because of increased complication rates and requires discontinuation of smoking for at least 2 weeks before and after surgery, although compliance is often uncertain.

Implant volumes ranged from 180 to 800 mL, with an average of 380 mL (Figure 2). Implant types used were McGhan (55.5%), Mentor (40.5%), and Micro-



**Figure 2.** Implant volume.

cell (4%; CUI). All implants had surface texturing. Most of the implants (90.7%) were placed in a sub-muscular position. The approach to placement of the implants was influenced by the patient's preference. Sixty-five percent of the patients preferred a transaxillary approach, whereas 35% preferred the periareolar incision.

### Deflation

Deflation occurred in 8 patients (3.9%). The deflations occurred anywhere from 2 weeks to 6.5 years after augmentation. They were all unilateral deflations: 4 in the right breast and 4 in the left. One patient had 2 deflations of the same side. None of the patients recalled a traumatic event related to the deflation. Most of the implants were replaced within a week of deflation. The manufacturer and the patient absorbed most of the cost of the replacement in every case.

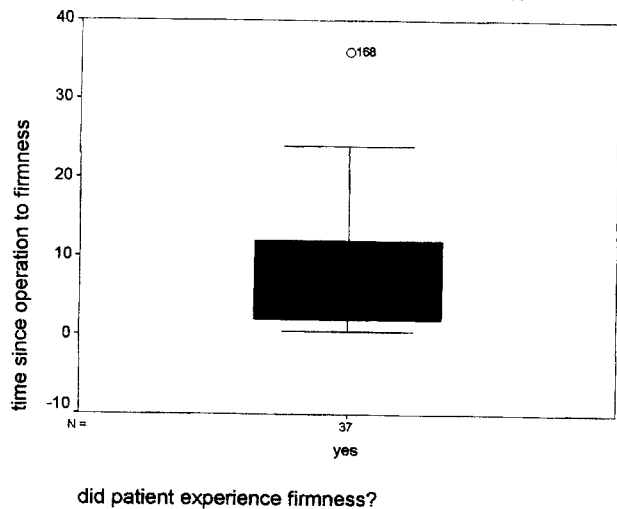
### Capsular Contracture

In this study the women were asked to rate their firmness according to a series of questions based on Baker's classification of capsular contracture. Baker III was assigned to patients who described their breast as firm but not uncomfortable. Baker IV was assigned to patients who described their breast as firm and uncomfortable. The use of this terminology reflects the ratings of capsular contracture by patient self-assessment versus the physician.

Overall, 39 patients (18.8%) reported firmness in their breasts. Sixteen of the patients (7.7%) reported that their breast was firm but not uncomfortable. Three of the patients (1.4%) reported firmness with discomfort.

The time elapsed between the augmentation procedure to reported firmness varied from 2 weeks to 3

### time since operation to firmness in month



**Figure 3.** A block graph representing the time elapsed from surgery to firmness as reported by the patient. The block represents 75% of responses and the horizontal line represents the 50% mark.

years. The majority of the cases were reported to occur within the first year, in contrast to silicone-gel implants, in which the rate of firmness increases with time (Figure 3).

Three of 39 patients underwent surgery for correction of firmness. Therefore, most of the patients did not desire surgery unless uncomfortable.

#### Infection

Nine of 207 patients (4.3%) reported an infection postoperatively. All infections reported were unilateral. Most of the infections were reported in the immediate postoperative period. Four of the 9 patients had minor infections at the incision site that responded to oral antibiotics. The other 5 patients had an incision and drainage and subsequent removal of the prosthesis. Reimplantation was not attempted until 4 months to 1 year after the removal of the infected implant. Two patients reported a delayed infection 3–4 weeks postoperatively. One patient developed a severe infection in her finger that spread to the axilla and the peri-prosthetic space 3.5 years after the augmentation. Two of the patients reimplanted had recurrent fluid accumulation that warranted incision and drainage and subsequent removal of the implant. In 1 of these patients, the offending organism was atypical mycobacterium fortuitum, for which the patient was placed on a multiple antibiotic regimen for 6 months before another attempt at reimplantation. The second patient failed 3 attempts at reimplantation, and no specific organism was ever isolated despite multiple cultures. This was considered to be an implant rejection.

#### Bleeding

Six of 207 patients (2.9%) reported to have some kind of bleeding postoperatively. The bleeding occurred within the first 10 days after surgery. Five out of the 6 patients had a periareolar incision. Two of the patients had a minor bleed that resulted in ecchymosis and bruising but did not require any treatment. Two other patients had undergone replacement of their silicone implants through a periareolar incision and capsulectomy. These patients required an incision and drainage. Finally, 2 of the patients required a hematoma evacuation in the operating room. All of the patients have done well subsequently.

#### Seroma

Four of 207 patients (1.9%) reported to have had fluid accumulation in their breast after surgery. One of these resolved spontaneously; the other 3 underwent an incision and drainage. Two of the 3 underwent removal of their silicone implants with capsulectomy and replacement with saline implants. Drains were placed at the time of surgery to prevent a seroma. None of the patients required additional surgery.

#### Pain

The patients were asked if they experienced any abnormal pain after their surgery, and they were asked to rate it as mild, moderate, or severe. Overall, 59 patients (28.5%) reported to have abnormal pain. Twenty-four patients (11.6%) reported to have mild pain that lasted, on average, 6.6 months; 28 patients (13.5%) reported to have moderate pain that lasted an average of 8.8 months; and 7 patients (3.4%) described their pain as severe. The patients describing their pain as severe reported the pain to last an average of 23.6 months.

#### Rippling

The patients were asked if they had any wrinkling or rippling of their implants. Ninety-two patients (44.4%) reported to have wrinkling. Wrinkling was not limited to visible waviness of the implant, but also waviness to the touch. This high percentage was surprising in view of the fact that 90.7% of the implants were placed in a submuscular position. Most of the rippling was reported to be at the inferior portion of the breast where the pectoralis major muscle and its outer fascial covering is detached and the inframammary fold is lowered. This confirms previous reports that saline-filled implants are associated with a significantly higher risk of wrinkling than gel-filled implants.<sup>5</sup> Furthermore, all implants used in this study were textured and therefore with a thicker shell. This factor increases chances of rippling as well.<sup>5</sup>

#### Loss of Nipple Sensation

Patients were asked if they experienced any loss of sensation and its duration. The dominant innervation of the nipple areola is the fourth lateral cutaneous intercostal branch. It enters laterally through the fourth

interspace and runs medially under the deep fascia for a few centimeters. It then courses upward through the breast tissue to supply the nipple-areolar complex. Overall, 84 of 207 patients (40.6%) reported some disturbance of nipple sensation. Thirty-seven of the patients (17.9%) reported this to be a temporary phenomenon. The average time that this temporary numbness lasted was 11.3 months. The majority of patients (47, or 22.7%) noted some degree of ongoing or permanent change. This significant change in nipple sensation is similar to previous reports by Fiala et al<sup>6</sup> who found that 41.6% of respondents to their survey reported to have some degree of permanent changes to their nipple sensation. This change in nipple sensation does not seem to be affected by the surgical incision.

#### *Other Numbness*

Patients were asked if they had any loss of sensation other than loss of nipple sensation. Overall, seventy-two patients (34.8%) reported to have other numbness. Forty-two patients (20.3%) described it as an ongoing or permanent numbness. It was surprising to note that more patients reported loss of nipple sensation. In addition, we observed that loss of nipple sensation was not directly related to numbness in other areas or vice versa. This may be due to the multiple sensory innervations of the breast, including the supraclavicular nerves from the third and fourth branches of the cervical plexus, the anterior cutaneous branches from the second to the sixth intercostals nerves, and the anterior branches of the third to sixth lateral cutaneous nerves.

#### *Overall Satisfaction*

The patients rated their satisfaction as follows: 110 (53%) responded as being highly satisfied, 68 (33%) were satisfied, 22 (10.6%) were fairly satisfied, and 7 of 207 (3.4%) reported as being not satisfied with their results. Lack of satisfaction was related to postoperative complications, mainly capsular contracture and wrinkling. When asked if they would do it again, 91% of the patients responded positively.

#### *Secondary Surgery*

Overall, 29 patients (14%) had additional surgery during this study period. Indications for this included replacement of a deflated implant, release of capsular contracture, removal of implant or drainage due to an infection, evacuation of a hematoma, and other breast surgery not related to the augmentation, such as biopsies.

### **Discussion**

To obtain the FDA's approval of saline-filled breast implants, the implant manufacturers Mentor and McGhan conducted clinical testing to determine the most common risks associated with the implants. One of the clinical studies assessed the 3-year cumulative risk rate of developing complications as well as patient satisfaction.<sup>3,4</sup>

One of the most common problems associated with

breast augmentation is capsular contracture. Moderate to severe capsular contracture may result in a hardened, deformed, and sometimes painful breast. The 3-year risk of developing capsular contracture III/IV was 9% according to the study presented by the manufacturers. In our study, 19 patients reported significant firmness (9.2% over 9 years). Over the years there have been modifications to breast implants and to the technique in order to decrease the incidence of capsular contracture. One such modification was surface texturization of the implants. Based on reports that textured surface implants reduce the rate of contracture,<sup>7-10</sup> the corresponding author used only textured surface implants during the study period. However, more recent reports have found that texturization of saline-filled implants did not reduce the incidence of capsular contracture.<sup>5,11,12</sup> Currently he is favoring smooth implants.

Another factor studied was implant size. There was no statistically significant relationship between implant volume and the likelihood of developing capsular contracture. However, in another study Handel et al<sup>5</sup> found that contracture occurred earlier in large (>350 mL) implants. Interestingly, the author found that smokers had a higher tendency (26.2%) to experience firmness to their breast compared with nonsmokers (15.2%). This was not statistically significant.

Not surprisingly, the author also found an increased risk of contracture in women who had bleeding or hematoma. Contracture occurred in 50% of cases complicated by bleeding as compared with 18% of cases without. This was found to be statistically significant ( $P < .05$ ). This is consistent with previously published studies that suggest that hematoma is a predisposing factor to development of capsular contracture.<sup>5,13-15</sup>

The effect of implant position was related to risk of developing capsular contracture. No significant difference was found in the rate of contracture as it related to implant position. This is contrary to the common belief that submuscular placement of implants reduces the risk of capsular contracture by the constant massaging of the implant by the muscle.<sup>16-18</sup>

Wrinkling was one of the factors that significantly affected the patients' overall satisfaction. The 3-year cumulative risk rate of wrinkling was reported by the implant manufacturers to be between 11% and 21%. Our patients reported a significantly higher rate of wrinkling (44.4%). This was a surprising finding since 90% of the implants were placed under the pectoralis major muscle. In fact, the position of the implant correlated highly with the likelihood of developing wrinkling. Overall, 75% of patients who had subglandular placement of their implants reported rippling versus 40% of those who had their implants in the submuscular position. This result was not related to the length of the study because most patients reported to have developed wrinkling within the first 7 months postoperatively. Furthermore, there was no statistically significant relationship between implant volume and likelihood of developing wrinkling.

This high rate of reported rippling reflects the fact that this is a subjective patient-reported finding as opposed to an examiner's findings. The patients were asked to report any wrinkling or waviness, whereas the manufacturers reported only moderate to severe rippling. In addition, all of the implants used in this study that had surface texturing and skin wrinkling have been correlated with surface texturing in previous studies.<sup>2</sup> Recently, to resolve the rippling, the corresponding author has been overfilling the implants with good success in selected patients. These patients are warned that their breasts are going to feel firmer. Unfortunately, the number of patients who had overfilled implants is not adequate for statistical analysis.

A significant number of patients reported having an alteration in nipple sensation, with 22.7% noting some degree of permanent change. These patient-reported results are higher than the 8–10% reported by the implant manufacturers. Interestingly, there was no statistically significant relationship between implant size and the likelihood of developing loss of sensation. Furthermore, there was no significant difference in the likelihood of developing loss of nipple sensation as it related to the site of implant insertion (periareolar versus transaxillary) in this study. Loss of nipple sensation was also found to be a statistically significant factor affecting patients' overall satisfaction. Patients who had ongoing or permanent loss of sensation were half as likely to be highly satisfied.

Despite the fact that augmentation mammoplasty is not devoid of problems, the satisfaction rate of women remains high. In this study, 96.6% of the patients were either fairly satisfied, satisfied, or highly satisfied with the results. Ninety-one percent would do it again. Of all the factors studied, capsular contracture and rippling had the most impact on the patient's overall satisfaction. Patients who experienced capsular contracture or rippling were more likely to be fairly satisfied or not satisfied with their breast implants.

### Conclusion

This retrospective study involved a detailed survey that was sent to patients who had undergone aesthetic breast augmentation at the institute from May 1992 to June 2000. The purpose of the study was to assess the incidence of postoperative complications as reported by patients and to identify factors related to their satisfaction. The surgical records of the respondents were reviewed. As with any survey, the response rate was less than 100%, which may introduce bias into the results. Patients with good postoperative results may be less inclined to respond to the survey. After 2 mailings our overall response rate was 45%. The patient population analyzed here is relatively small, and therefore the results may represent a lack of statistical power sufficient to demonstrate minor influences on the possible complications and patient satisfaction.

Based on the author's experience and the results of the patient survey, the following conclusions can be ascertained:

1. Capsular contracture remains one of the main complications affecting patient satisfaction. In the corresponding author's practice, the risk rate of developing capsular contracture is approximately 1% per year. Implant volume and position had no significant effect on the risk of developing capsular contracture, although it seems that contracture occurs earlier in larger implants. There is a higher tendency for smokers to develop firm breasts.
2. Leakage is generally due to mechanical failure of the implant. It is more of a matter of inconvenience to the patient and is easily correctable. Implant deflation does not have a significant effect on patient satisfaction. Our deflation rate was less than 0.5% per year.
3. Infection, although rare, may have a devastating effect on the patient. More often than not the implant must be removed and left out for an extended period of time. The surgeon should be cognizant of the possibility of mycobacterium fortuitum infection, which may present as a delayed infection.
4. Pain is a significant factor when implants are placed in a submuscular position. Implant volume did not correlate with the degree of pain.
5. Bleeding is a contributing risk factor to capsular contracture. Transaxillary endoscopic dissection allows direct visualization of the surgical field and absolute hemostasis.
6. Loss of nipple sensation did not correlate with the implant size or incision site. Nonetheless, a significant number of patients (22.7%) reported ongoing or permanent loss of sensation.
7. Skin wrinkling is a significant factor with saline-filled implants. Wrinkling is more common with subglandular placement of the implants, but it is not uncommon even when the implants are placed in a submuscular position. Implant size did not correlate with the risk of developing skin wrinkling. Previous studies have shown that surface texturing is a contributing factor to skin wrinkling. Most importantly, wrinkling correlates highly with patient satisfaction.

For millions of women who have undergone breast augmentation, the procedure has resulted in an aesthetic appearance that has improved their self-image and quality of life. Although breast implants are not devoid of problems, as long as their benefit to the patient outweighs the risks they will be considered safe devices. As clinicians it is our duty to inform our patients of the possible risks associated with the procedure so they can make an educated decision.

### References

1. Kessler DA. The basis of the FDA's decision on breast implants. *N Engl J Med.* 1992;326:1713–1715.
2. Guerrero JS, Colditz GA, Karlson EW, Hunter DJ, Speizer FE, Liang MH. Silicone breast implants and the risk of connective-tissue disease and symptoms. *N Engl J Med.* 1995;332:1666–1670.
3. Mcghan Medical Corporation. *Saline-filled*

*Breast Implant Surgery: Making an Informed Decision*. Santa Barbara, Ca: McGhan; 2000.

4. Mentor Corporation. *Saline-filled Breast Implant Surgery: Making an Informed Decision*. Santa Barbara, Ca: McGhan, 2000.

5. Handel N, Jensen JA, Black Q, Waisman JR, Silverstein MJ. The fate of breast implants: A critical analysis of complications and outcomes. *Plast Reconstr Surg*. 1995;96:1521–1533.

6. Fiala TGS, Andrew Lee WP, May JW. Augmentation mammoplasty: Result of a patient survey. *Ann Plast Surg*. 1993;30:503–509.

7. Ersek RA. Rate and incidence of capsular contracture: A comparison of smooth and textured silicone double-lumen breast prosthesis. *Plast Reconstr Surg*. 1991;87:879–884.

8. Coleman DJ, Foo ITH, Sharpe DT. Textured or smooth implants for breast augmentation? A prospective controlled trial. *Br J Plast Surg*. 1991;44:444–448.

9. Hakelius L, Ohlsen L. A clinical comparison of the tendency to capsular contracture between smooth and textured gel-filled silicone mammary implants. *Plast Reconstr Surg*. 1992;90:247–254.

10. Burkhardt BR, Demas CP. The effect of Siltex texturing and povidone-iodine irrigation on capsular contracture around saline inflatable breast implants. *Plast Reconstr Surg*. 1994;93:123–128.

11. Tarpila E, Ghassemifar R, Fagrell D, Berggren

A. Capsular contracture with textured versus smooth saline-filled implants for breast augmentation: A prospective clinical study. *Plast Reconstr Surg*. 1997;99:1934–1939.

12. May JW, Bucky PL, Sohoni S, Ehrlich HP. Smooth versus textured expander implants: A double-blind study of capsule quality and discomfort in simultaneous bilateral breast reconstruction patients. *Ann Plast Surg*. 1994;32:225–232.

13. Higgs CJ, Raju DR, Straith RE. Influence of some operative and post-operative factors on capsular contracture around breast prostheses. *Plast Reconstr Surg*. 1978;61:384–389.

14. Wagner H, Beller FK, Pfautsch M. Electron and light microscopy examination of capsules around breast implants. *Plast Reconstr Surg*. 1977;60:49–55.

15. Watson J. Some observations on breast augmentation procedures over the past two decades. *Aesth Plast Surg*. 1976;1:89.

16. Puckett CL, Croll GH, Reichel CA, Concannon MJ. A critical look at capsule contracture in subglandular versus subpectoral mammary augmentation. *Aesth Plast Surg*. 1987;11:23–28.

17. Biggs TM, Yarish RS. Augmentation mammoplasty: Retropectoral versus retromammary implantation. *Clin Plast Surg*. 1988;15:549–555.

18. Vasquez B, Given KS, Houston GC. Breast augmentation: A review of subglandular and submuscular implantation. *Aesth Plast Surg*. 1987;11:101–105.